

Executive summary of the 11th HHT international scientific conference

Helen Arthur¹ · Urban Geithoff² · James R. Gossage³ · Christopher C. W. Hughes⁴ · Pascal Lacombe⁵ · Mary E. Meek⁶ · Paul Oh⁷ · Beth L. Roman⁸ · Scott O. Trerotola⁹ · Sebastiaan Velthuis¹⁰ · Whitney Wooderchak-Donahue¹¹

© Springer Science+Business Media Dordrecht 2015

Abstract Hereditary hemorrhagic telangiectasia (HHT) is a hereditary condition that results in vascular malformations throughout the body, which have a proclivity to rupture and bleed. HHT has a worldwide incidence of about 1:5000 and approximately 80 % of cases are due to mutations in *ENG*, *ALK1* (aka activin receptor-like kinase 1 or *ACVRL1*) and *SMAD4*. Over 200 international clinicians and scientists met at Captiva Island, Florida from June 11–June 14, 2015 to present and discuss the latest research on HHT. 156 abstracts were accepted to the meeting and 60 were selected for oral presentations. The first two sections of this article present summaries of the basic science and clinical talks. Here we have summarized talks covering key themes, focusing on areas of agreement, disagreement, and unanswered questions. The final four sections summarize discussions in the Workshops, which were theme-based topical discussions led by two moderators. We hope this overview will educate as well as inspire those within the

field and from outside, who have an interest in the science and treatment of HHT.

Keywords HHT · Hereditary hemorrhagic telangiectasia · Endoglin · ALK1 · Arteriovenous malformation · Epistaxis

Summary of basic science talks

Whitney Wooderchak-Donahue

Advances in HHT genetics

HHT is caused by mutations in the transforming growth factor-beta (TGF- β) signaling pathway genes *ENG*, *ALK1*, and *SMAD4* [1–3]. Yet, approximately 15 % of individuals identified as having HHT currently have no known genetic cause [4]. This year's meeting began when Hata and

✉ James R. Gossage
jgossage@gru.edu

¹ Institute of Genetic Medicine, Centre for Life, Newcastle University, Newcastle upon Tyne, UK

² Department of Otorhinolaryngology, Essen University Hospital, Essen, Germany

³ Department of Medicine, Georgia Regents University, Augusta, GA, USA

⁴ Department of Molecular Biology and Biochemistry, University of California Irvine, Irvine, CA, USA

⁵ Department of Diagnostic and Interventional Radiology, Hôpital Ambroise Paré, Université de Versailles, Assistance Publique-Hôpitaux de Paris, Boulogne-Billancourt, France

⁶ Department of Interventional Radiology, University of Arkansas for Medical Sciences, Little Rock, AR, USA

⁷ Department of Physiology and Functional Genomics, University of Florida College of Medicine, Gainesville, FL, USA

⁸ Department of Human Genetics and Vascular Medicine Institute, University of Pittsburgh, Pittsburgh, PA, USA

⁹ Department of Radiology, Perelman School of Medicine, University of Pennsylvania, Philadelphia, PA, USA

¹⁰ Department of Cardiology, St. Antonius Hospital, Nieuwegein, The Netherlands

¹¹ ARUP Institute for Clinical and Experimental Pathology, Department of Pathology, University of Utah, Salt Lake City, UT, USA

colleagues revealed that *DROSHA*, a gene involved in miRNA biogenesis, may play a role in HHT. *DROSHA* variants identified in HHT patients with no known mutation disrupted microRNA biogenesis and caused vascular leakage in vivo.

Marchuk and colleagues (see Abstract OR12) reported on the challenges of using exome sequencing to identify new HHT causative genes. Using an innovative statistical approach, they concluded that high standards are necessary to label a gene mutation as causative versus part of the overwhelming “sea of variant noise” in such datasets. Instead of looking for new HHT genes, VanSant-Webb and colleagues (see Abstract OR14) showed that many HHT patients with no known genetic cause may have a deleterious non-coding region variant in a known HHT gene. Additional experiments may reveal that non-coding regions play a larger role in HHT disease pathogenesis.

Improving HHT molecular diagnostics

With the advent of next generation sequencing (NGS), a new era for HHT molecular diagnostics has begun [5]. Brusgaard and coworkers (see Abstract OR17) and Wooderchak-Donahue and coworkers (see Abstract OR21) described how they established multi-gene NGS panels for the rapid molecular diagnosis of HHT. Molecular diagnosis may become instrumental in guiding future therapies as only certain HHT mutation carriers may be eligible to receive ataluren, a treatment currently in clinical trials for other genetic disorders (see Abstract OR43) [6, 7].

BMP9 and HHT

Bone morphogenetic 9 gene (*BMP9/GDF2*) mutations were recently identified in several individuals suspected to have HHT who previously tested negative for *ENG*, *ALK1*, and *SMAD4* mutations [8]. Because *BMP9* mutations affect a much smaller number of HHT-like patients [8], it's not surprising that Topping and coworkers (see Abstract OR31) did not identify any *BMP9* mutations in 12 Danish HHT families who previously tested negative for a known HHT gene mutation. Interestingly, Friesel and coworkers (see Abstract OR28) described new links between BMP9 signaling and the Hippo pathway which may reveal novel mechanisms in the etiology of HHT.

Expanding the genotype–phenotype overlap observed among HHT and pulmonary arterial hypertension (PAH) patients [9], Bailly and coworkers (see Abstract OR29) reported on the potential involvement of BMP9 in PAH. Although BMP9 is the most potent ligand of the ALK1/BMPR2 signaling pathway, their preliminary results suggest that *Bmp9* knockout mice are surprisingly protected against the development of pulmonary hypertension under hypoxic conditions. It will be interesting to

explore the mechanism behind this unexpected observation.

Understanding molecular mechanisms in HHT to drive therapeutic discovery

Can HHT be treated by upregulating the remaining normal copy of the gene to potentially restore normal protein levels? Oh and coworkers (see Abstract OR18) showed that ALK1 upregulation suppressed the characteristic development of wound-induced skin arteriovenous malformation (AVM) formation in *Eng*-deficient mice. These data support the concept that endoglin and ALK1 are part of a linear signaling pathway involved in the proper formation of arteriovenous interconnections through capillary beds. Potentially, ALK1 over-expression/activation could be an effective therapeutic strategy for HHT1 patients.

Multiple investigators explored how wound healing and inflammation can “trigger” the development of HHT vascular lesions. Oh and Kim (see Abstract OR37) revealed how macrophage recruitment rather than angiogenic stimulation plays a critical role in the formation of AVM in *Alk1*-deficient wounded skin. Su and colleagues (see Abstract OR38) described how the consistent infiltration and pro-inflammatory differentiation of HHT mutated monocytes contributes to the pathogenesis of AVM formation. Bernabeu and coworkers (see Abstract OR56) revealed that a complex gene expression network is triggered during vascular wounding involving KLF6 and MMP14 to drive soluble endoglin release in sprouting endothelial cells surrounding the wound border. Finally, Nachtigal and coworkers (see Abstract OR3) showed that inflammation results in reduced expression of the membrane-bound form of endoglin and endothelial nitric oxide synthase (eNOS), and that atorvastatin, a drug that prevents inflammation, induced eNOS expression and upregulated endoglin levels in endothelial cells. Collectively, these findings demonstrate that inflammation is involved in the formation of HHT lesions.

Ola and coworkers (see Abstract OR45) investigated AVM formation during development using a mosaic, tamoxifen-inducible endothelial cell-specific *Alk1*-deficient mouse model. Targeting VEGFR2 signaling rescued AVM formation in the retinal vasculature. Their results indicate that downstream VEGFR2 signaling targets such as AKT1 may be a novel means to treat HHT vascular malformations.

Because Notch and ALK1 signaling have been shown to interact [10], several investigators explored if Notch signaling plays a role in HHT AVM pathogenesis. Roman and coworkers (see Abstract OR55) demonstrated that AVMs in *alk1* mutant zebrafish arose independently of perturbations in Notch signaling, suggesting that Notch signaling may not be critical for AVM formation in HHT. However,

Huang and coworkers (see Abstract OR54) reported that NOS inhibition attenuated the formation of Notch-mediated brain AVM formation in vivo. Further investigation may reveal novel mechanisms underlying brain AVM formation in HHT.

New approaches to study HHT biology

Several innovative approaches to study cell signaling in HHT were discussed. Orlova and coworkers (see Abstract OR16) revealed how they developed a human system to model HHT1 endoglin deficiency using patient-derived induced pluripotent stem cells (iPSCs). These HHT1 patient-specific iPSCs represent a renewable, scalable source for endothelial cells to model disease for future studies. Next, Bowers and coworkers (see Abstract OR1) described an assay using three-dimensional endothelial cell matrices to interrogate capillary network formation. Such assays can be used to more clearly define the underlying pathogenic basis for vascular anomalies in HHT.

Moving forward

Certain questions remain unanswered regarding the molecular pathogenesis of HHT. For ~15 % of HHT patients who do not have an identifiable mutation, are additional causative genes or genetic modifiers contributing to their phenotype, or are deep intronic regulatory variants in known HHT genes responsible? Second, what dictates the formation of AVM in HHT? Is AVM formation caused by developmental defects and a loss of expression of both relevant gene copies (i.e. second somatic hit in the lesion), or is AVM formation driven by vascular wounding and inflammation? Answers to these questions will help define the course for future pharmacological interventions to help treat HHT patients world-wide.

Summary of clinical talks

Mary E. Meek and Sebastiaan Velthuis

Diagnosis of HHT

Recurrent, spontaneous epistaxis and telangiectases are diagnostic criteria for HHT, but the optimal clinical application of these criteria is unknown. McDonald and colleagues (see Abstract OR13) studied the incidence of telangiectases and non-traumatic epistaxis in 189 non-HHT patients. The median number of epistaxis in non-HHT patients was 1 every 2 years with 95 % of patients having <2 per month. Furthermore, 95 % of patients had ≤3 telangiectases. They proposed new “cut-offs” for

diagnostic criteria of >2 epistaxis/month and >4 telangiectases in characteristic sites.

Geisthoff and colleagues (see Abstract OR60) presented a retrospective review of patients with HHT, comparing the age of onset of symptoms to the age at diagnosis. They found a mean age of symptoms at 25 years but 11 % did not develop symptoms until after age 50. This re-emphasizes the importance of genetic testing as there may be a delay in symptom presentation.

McDonald and colleagues (see Abstract OR20) evaluated the clinical sensitivity of genetic testing in patients who had 3 or more Curaçao criteria for the diagnosis of HHT. When the criteria were strictly applied, 96 % of those patients had either an *ENG* or *ALK1* mutation.

Use of contrast echocardiography to diagnose pulmonary arteriovenous malformations

Pulmonary arteriovenous malformations (PAVM) are low-resistance, high-flow abnormal vascular structures that most often connect a pulmonary artery to a pulmonary vein resulting in right-to-left shunt (RTLS) [11]. The normal pulmonary capillary network measures 8–10 microns in diameter, which acts as a filter. PAVM predispose patients to complications from paradoxical systemic embolization of both thrombotic and septic origin, including stroke and brain abscess [12–15]. Transthoracic contrast echocardiography (TTCE) is the first-line screening technique for the detection of PAVM in HHT [16].

TTCE is usually performed by injecting agitated saline, which is flushed between syringes to create microbubbles. Gelofusine has been described as an alternative contrast agent with higher density and potentially smaller and more stable microbubbles. Parra and colleagues (see Abstract OR49) prospectively compared TTCE using agitated saline versus Gelofusine in 120 HHT patients. They found poor agreement between the two contrast agents (Kappa 0.32) and a higher shunt grade with Gelofusine. As chest computed tomography (CT) can be deferred in patients with minimal or no shunt on TTCE [17], the use of Gelofusine may result in more unnecessary chest CT scans.

Jyothidasen and colleagues (see Abstract OR51) reported increased accuracy in differentiating cardiac versus intrapulmonary shunts on TTCE by looking for a “ramping up” pattern of contrast appearance. This is an important observation, especially in those challenging cases with early appearance of microbubbles within three cardiac cycles after entering the right ventricle, and helps distinguishing large proximal PAVM from cardiac shunts like a patent foramen ovale.

Previously, there have been concerns about the safety of TTCE, as the injection of a small amount of air (0.5–1 ml) may impose risk for systemic air emboli in patients with

possible RTLS. Gazzaniga and colleagues (see Abstract OR50) addressed this important issue in a large prospective study of 617 consecutive patients. They found adverse effects in only 2.4 % of HHT patients screened with TTCE, all within 2–25 min after the agitated saline injection. Events included migraine, blurred vision, numbness, paresthesias and nausea, all of which occurred in patients with RTLS. Side effects were positively correlated with the TTCE shunt grade and resolved quickly without residual side effects. These findings confirm that TTCE is a safe diagnostic tool and its benefits strongly outweigh its potential (minor) risk.

Long term follow-up of PAVM

Still not well established is the appropriate screening interval for patients with mild or no RTLS on TTCE. Latino and colleagues (see Abstract OR25) did a retrospective review of 129 adult patients with negative TTCE at presentation who were rescreened at 5, 10 and 15 years with TTCE. Although 45 % of patients had a positive TTCE at 5 years, no clinically significant PAVM were identified in patients rescreened up to 15 years after the initial negative TTCE.

Vorselaars and colleagues (see Abstract OR26) retrospectively reviewed the progression of RTLS grade (0–3) in 199 HHT patients who had repeat TTCE at 5 years. 18.1 % demonstrated an increase in RTLS grade at 5 years while 7.5 % showed a decrease. Ten patients who were initially grade 1 increased to grades 2, and 3 of these developed treatable PAVM. Amongst all grades, 6 % developed a treatable PAVM during follow up. No patients without RTLS developed treatable PAVM at 5 years.

These presentations prompted much discussion regarding the establishment of a longer screening interval in low grade shunts and potentially not rescreening adult patients who were initially negative. The importance of low grade RTS is further obscured by the findings that 6–28 % of the normal population has a low grade positive TTCE [17–19].

Diederik and colleagues (see Abstract OR41) presented their findings of a 28 % reperfusion rate after PAVM embolization in 293 adults with HHT. They found that treatment success depended more on the location of embolization and type of PAVM rather than on the material used, as there was no difference between the use of coils or plugs. It was also suggested that embolization of the PAVM sac itself instead of its feeding vessel might be more effective to prevent reperfusion, especially in the more complex PAVM, but some experienced interventional radiologists in the audience disagreed.

Trerotola and colleagues (see Abstract OR27) emphasized the need for new consensus criteria by demonstrating the lack of consensus in his survey results of HHT Centers

worldwide regarding the management and follow-up of PAVM with feeding arteries <3 mm. The results of this survey showed wide variability among clinicians regarding screening methods and interval, recommendations regarding embolic protection (IV filters, antibiotics), and size criteria for embolization.

Management of PAVM in children

Unlike the adult HHT population, comparative studies on PAVM in children with HHT are lacking and therefore the optimal screening and management of this subgroup was highly debated. Determinants of adverse events and indications for treatment are largely unknown and concerns exist on safety and high incidence of reperfusion of treated PAVM in otherwise asymptomatic children.

Ibrahim and colleagues (see Abstract OR34) demonstrated a clear correlation between non-invasive oxygen saturation and serious adverse events (SAE) in a cohort of 164 HHT children up to 15 years of age (mean 9.6 years) during a 12-year period. They found SAE in 5 % of all children of which 63 % were PAVM-related (e.g. respiratory insufficiency, hemoptysis, cerebral abscess or death). Importantly, all children with PAVM-related SAE had an oxygen saturation ≤ 92 % (71–92 %) at baseline. They concluded that screening for PAVM in children with pulse oximetry appears to be safe and that chest CT or TTCE may be withheld until around age 16. These results need to be confirmed in future (large) studies.

White and colleagues (see Abstract OR15) evaluated the correlation between symptoms and PAVM in 52 children with known PAVM, of whom 32 (62 %) were asymptomatic. Of these asymptomatic patients, 17 had a PAVM with a feeding vessel >3 mm and 2 patients had diffuse PAVM. The average non-invasive oxygen saturation of the asymptomatic group was 96 % compared to 93.6 % in the symptomatic group. There was a discussion following this presentation about using a 6-min walk test to evaluate these patients in addition to the presence or absence of symptoms [20].

Treatment of small PAVM in asymptomatic children is controversial due to the potentially increased incidence of complications such as formation of systemic collaterals, hemorrhage, and recanalization. Crawford and colleagues (see Abstract OR35) retrospectively reviewed their long-term outcomes of embolization therapy in 14 children (≤ 18 years) with HHT. They indeed found a high rate of PAVM persistence (70 %) during a mean follow-up of 9.7 years, which was significantly higher than previously reported [21].

The clinical significance of PAVM persistence after embolization in children remains controversial and re-interventions should be based on a case-by-case risk–benefit

analysis. The audience agreed that larger multi-center studies on pediatric PAVM embolization outcomes are needed in order to decide on the best management strategy—especially in asymptomatic children.

Medical treatment of epistaxis in HHT

Recurrent spontaneous epistaxis is the most common symptom of HHT and a major HHT-related health concern affecting quality of life. There were interesting reports on the treatment of epistaxis both medical and surgical.

Gossage and colleagues (see Abstract OR46) presented the results of the NOSE trial (North American Study of Epistaxis in HHT). This was a double-blind randomized controlled trial examining the safety and efficacy of three nasal sprays versus placebo in 121 patients with moderate to severe epistaxis. Patients were randomized to receive 12 weeks of either bevacizumab 1 %, estriol 0.1 %, tranexamic acid 10 % or saline (placebo). All drugs were well tolerated. Placebo resulted in a modest improvement in epistaxis severity score (ESS) and nosebleed frequency. Bevacizumab and tranexamic acid were no better than saline and estriol spray was worse than placebo by several measures. Of special interest was the large potential placebo effect and the observed discrepancy between high subjective improvements compared to only mild objective reductions in epistaxis, which should warn us for subjective measurements in future epistaxis studies. It was suggested that the bevacizumab dose may have been too low.

Meir and colleagues (see Abstract OR9) reported on 6 patients who received 1.5 % propranolol gel intranasally twice daily for 2 months. Treatment was generally well tolerated and resulted in a decrease in ESS from a mean of 7.3 to 4.5.

Smith and colleagues (see Abstract OR44) found that patients with HHT2 had significantly higher ESS compared to HHT1. Retrospective analysis of 45 patients who received antifibrinolytic therapy showed a decrease in ESS with a follow-up of 12.7 months. The minimum clinically meaningful change in ESS and whether this response to antifibrinolytic therapy is genotype-dependent are currently unknown.

Botella and colleagues (see Abstract OR5) presented the results of oral bazedoxifene treatment in 5 post-menopausal patients with HHT. A dose of 20 mg daily over 3 months resulted in a reduction in frequency and severity of epistaxis. The mechanism of action is felt to be from increasing expression of ALK1 and endoglin thereby decreasing expression of VEGF.

The results of seven patients who received 100 mg oral doxycycline twice daily were presented by Meek and colleagues (see Abstract OR10). Treatment for 30 days reduced mean ESS from 4.9 to 2.4. There was discussion

whether the mechanism of action related to MMP-9 inhibition and/or the change in nasal flora from the antibiotic action of the drug.

Iyer and colleagues (see Abstract OR47) presented 9 consecutive patients with severe, transfusion-dependent epistaxis and gastrointestinal bleeding who were treated with intravenous bevacizumab. At 9 months follow-up they found a marked decrease in the ESS from 9.1 to 2, cessation of transfusion in 89 %, and improvement in quality of life. No serious side effects were observed. Arizmendez and colleagues (see Abstract OR48) reviewed the literature on intravenous bevacizumab therapy in HHT. Most reports consisted of case reports with limited quality of evidence and dramatic variability in dosages and outcomes, although most studies showed improvement. Future multi-center studies are needed to evaluate the dose response curve and whether dosing should be corrected for body weight.

Surgical treatment of epistaxis in HHT

In addition to medical therapies, changes in surgical techniques were also presented. Piccirillo and colleagues (see Abstract OR11) described their mostly in-office technique of direct puncture sclerotherapy using sodium tetradecyl sulfate (STS) to treat epistaxis in 133 patients with HHT. After one complication of blindness, they changed from using a saline/STS mixture to a low pressure air/STS foam and have had no further serious complications.

Wilson and colleagues (see Abstract OR57) described a surgical technique modifying the traditional three-flap closure of the nostril in the Young's procedure to a two-flap closure. The short term results showed faster procedure time (1.4 vs 3.1 h) and comparable efficacy for the two-flap method versus the tradition method.

Whitehouse and colleagues (see Abstract OR58) described the use of a porcine-derived mucosal graft to resurface the nasal septum as opposed to standard skin grafts. Short-term benefits of this procedure are decreased dryness and crusting and no pain related to a skin-graft donor site, but long term effects are unknown.

Other presentations of interest

Although the RTLS grade on TTCE has been demonstrated to be strongly associated with the prevalence of cerebral ischemic events in HHT patients [15], other risk factors for PAVM-related cerebral complications are lacking. In a cohort of 497 consecutive patients with CT-proven PAVM, Shovlin and colleagues (see Abstract OR40) found that stroke risk was associated with iron deficiency rather than conventional neurovascular risk factors. Additional studies suggested enhanced platelet aggregation in iron deficiency

as a potential explanation, and this was exacerbated by serotonin. Whether selective serotonin reuptake inhibitors might decrease ischemic stroke risk—without increasing epistaxis or gastrointestinal bleeding—will be determined in future studies.

Pulmonary hypertension (PH) is increasingly recognized in HHT. Vorselaars and colleagues (see Abstract OR52) presented the first study that estimated the prevalence of all-cause PH in a cohort of 277 genetically confirmed HHT patients compared to 106 controls. A right ventricular systolic pressure ≥ 36 on echocardiography was identified in 9 % of HHT1 and 18 % of HHT2, compared to 4 % in controls. The presence of hepatic arteriovenous malformations (HAVM) and subsequent high cardiac output was a strong predictor for presence of increased pulmonary pressure. Isolated pulmonary arterial hypertension (PAH) was rare and only found in HHT2 (1.3 %). Despite the occasional description of PAH in HHT1 [22], there was consensus by the audience that true isolated PAH has never been reported in HHT1. Given the poor prognosis of untreated PH, screening for PH with echocardiography is warranted in all patients with HHT.

Harrison and colleagues (see Abstract OR32) reported a retrospective evaluation for high output heart failure in 134 patients using B-type natriuretic peptide (BNP). A cut-off of BNP >100 pg/mL had a sensitivity of 90 %, specificity of 84 %, and a negative predictive value of 99 % for high-output heart failure. This was recommended as a screening tool followed by right heart catheterization as the confirmatory test.

Although 90 % of HAVM appear to be asymptomatic, complications like high-output heart failure with PH, portal hypertension, and biliary ischemia may occur. McWilliams and colleagues (see Abstract OR33) proposed a classification scheme using abdominal CT to predict those HHT patients at highest risk of developing complications from HAVM. In 298 patients, contrast-enhanced CT demonstrated HAVM in 45 %. Only diffuse HAVM were related to adverse outcomes. In this group a common hepatic artery diameter ≥ 10 mm (grade 3) appeared to be the best predictor for adverse outcomes with an incidence of 39 versus 9 % in those with a diameter <10 mm (grade 1). Before adding abdominal CT to the screening protocol, this proposed grading system should be validated in a larger cohort with longer follow-up.

Workshop 1: What is the role of second hits in the development of AVMs?

Paul Oh and Beth L. Roman

Haploinsufficiency is widely considered to be the mechanism of HHT, but the variable age of onset and

expressivity suggest that “second hits,” or factors in addition to heterozygosity, determine disease outcome. These factors may be genetic, biochemical, and/or environmental. The goals of this workshop were to critically review the current state of knowledge regarding possible second hits and to set priorities for further research.

Genetic hits

Regarding genetic factors, the primary focus of the discussion was a possible role for somatic mutations—resulting in localized biallelic loss-of-function—in AVM and telangiectasia development. There is ample experimental evidence derived from animal studies suggesting the necessity of a somatic second hit for AVM development: both mouse and zebrafish models of HHT require homozygous mutation for a fully penetrant phenotype [23–31]. However, no experimental data from human subjects support this notion. There is one published report estimating cell surface endoglin at approximately 50 % of normal within HHT1-related AVM ($N = 2$), and Sanger sequencing of one of these AVM showed the expected wild type and mutant allele [32]. These data were interpreted as supporting haploinsufficiency. However, sequence data outside of the region surrounding the germline mutation were not shown; therefore, the role of somatic mutation could not be evaluated. We discussed the possibility that somatic mutations, potentially in circulating endothelial progenitor cells that might contribute to multiple vessels, might be a critical factor in lesion development, and we agreed that application of deep sequencing technologies to HHT lesions is required to properly address this possibility.

Biochemical hits

A second mechanism that might generate a localized decrease in functional protein is extracellular domain shedding. The extracellular ligand-binding domain of endoglin can be cleaved by matrix metalloproteinase 14 (MMP14) to produce a soluble form of endoglin that functions as a ligand sink [33]. In heterozygous cells, increased endoglin shedding—for example, as part of an inflammatory or hypoxic response [34]—might lower endoglin levels below a threshold required for maintenance of normal arteriovenous connections. Whether the ALK1 extracellular ligand-binding domain can be shed is unknown; however, endoglin shedding could effectively lower ALK1 signaling, given its ability to maximize BMP9/10-mediated ALK1 activity [35]. The possibility was also considered that stochastic events that transiently lower HHT-associated gene transcription may decrease functional protein below a threshold level and play a critical role in lesion development.

Environmental hits

Also discussed was the role of environmental factors. Evidence was reviewed from zebrafish demonstrating that AVM in *alk1* homozygous mutants are not genetically determined but require blood flow [36], and evidence from adult mice was discussed demonstrating that skin and brain AVM require both induced homozygous deletion of *Alk1* or *Eng* plus an angiogenic or inflammatory stimulus, such as VEGF treatment or wounding [28, 37–41]. These data from animal models strongly support the idea that, in addition to heterozygous mutation, vascular lesion development requires not only a second genetic or biochemical hit resulting in decreased functional ALK1 or endoglin protein, but also a third environmental hit to trigger angiogenesis, inflammation, and/or vascular remodeling. It will be important to further explore this paradigm both in laboratory models and in HHT patients.

Workshop 2: Why do mutations in *ALK1* and *ENG* result in moderately different phenotypes?

Helen Arthur and Christopher C. W. Hughes

The goal of this workshop was to consider why HHT1 and HHT2 patients have a different, albeit overlapping, profile of clinical symptoms. This was discussed by raising a series of questions to the workshop attendees and discussion of each one in turn.

Q1. Considering the profile of clinical symptoms in Fig. 1 (based on several publications [42–47]) it was agreed that the profile of clinical symptoms and age of onset in HHT1 and HHT2 are different—why might this be?

It was pointed out that overall in HHT the most highly affected vascular beds are exposed to challenging external environments and typical sites of inflammation (e.g. nose, gastrointestinal tract and skin). Inflammation is considered to be an important trigger, and recent work from Oh and colleagues presented at the meeting (see Abstract OR37) showed that macrophages may be important in arteriovenous malformations (AVM) formation. Interestingly, it was suggested that mucosal telangiectases are more indicative of HHT than dermal telangiectases and that in diagnosis one mucosal lesion is worth several dermal telangiectases!

The location of the source of circulating BMP9/10 ligands was considered. The major source of BMP9 is the liver, whilst BMP10 is found in the right atrium of heart. If these are main sources of circulating forms of these ligands, then circulating BMP9 and BMP10 concentrations

may be higher in the lung circulation than systemic arteries. Interestingly both endoglin and ALK1 protein expression is very high in lung endothelial cells so it is possible that there is the highest degree of ligand binding in the lung. A comment was made that ALK1 protein is not detectably expressed in liver sinusoids, yet HHT2 is characterized by a higher incidence of hepatic AVM.

Q2. Is expression of endoglin more venous and ALK1 more arterial?

It was agreed that evidence from animal studies suggests endoglin expression is more venous and ALK1 more arterial, but also agreed that ALK1 expression was upregulated by blood flow (shown by work in zebrafish by Corti and colleagues [36]). It was also considered that endoglin protein could be shed from arterial endothelial cells and/or endocytosed and this may explain reduced endoglin expression in arteries compared with veins. Transcript data should help to further characterize the relative expression of endoglin and ALK1 in arteries and veins. The importance of using freshly isolated primary cells in these types of studies was emphasized because endothelial cells rapidly change their phenotype during cell culture.

Pulsatile flow is important to maintain vessel integrity. Heart failure patients given a ventricular assist device can develop bleeding AVM [48], whilst congenital heart patients following certain surgeries producing non-pulsatile flow also develop AVM. For example, the classic Glenn anastomosis to connect superior vena cava to right pulmonary artery leads to pulmonary AVM with a reported incidence up to 25%. The interesting possibility was raised that loss of pulsatile flow may reduce ALK1 expression leading to AVM.

The threshold of endoglin protein expression may be key to HHT tissue specificity. For example, HUVEC normally express high levels of endoglin protein so reduced levels in HHT1 may not affect HUVEC function and telangiectases are not found in the umbilical cord. Other tissues which normally have lower levels of endoglin in physiological conditions may be more susceptible to vascular malformations when levels are further reduced in HHT1 patients. Therefore loss of endoglin below threshold levels may be a factor to explain tissue specificity of vascular lesions in HHT1. A similar threshold effect may apply to ALK1 expression in HHT2.

Using the mouse retinal model to investigate vessel development, it has been shown that AVM express venous markers [10, 25, 49]. New unpublished data presented at the meeting by Ola and colleagues (see Abstract OR45) using the same model showed that mosaic loss of *Alk1* in arteries gave no AVM but mosaic loss in veins did lead to AVM, suggesting AVM were venous in origin.

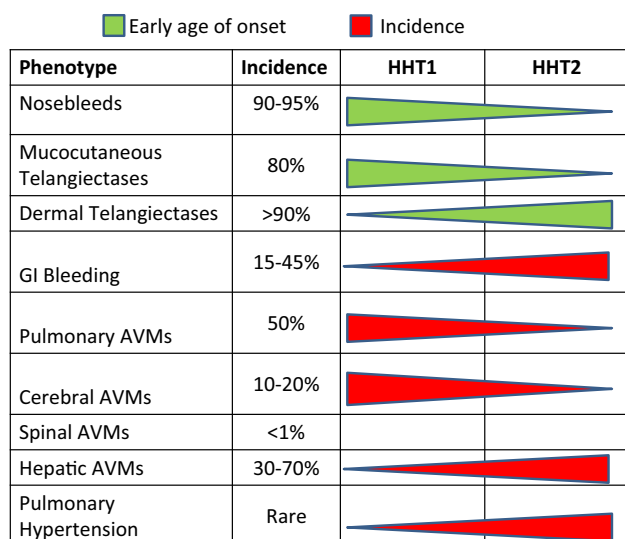


Fig. 1 Profile of clinical symptoms in HHT1 and HHT2. This table summarizes the relative age of onset and incidence of clinical symptoms in HHT1 and HHT2. The *thicker part* of the *triangle* is located in either HHT1 or HHT2 according to which disease has earlier age of onset (*green*) or higher incidence (*red*) of each of the listed clinical symptoms. Data are compiled from references [42–47]

A detailed study of ALK1 expression is merited, especially in the liver. It was noted that PF-03446962, an anti-ALK-1 humanized monoclonal antibody, showed benefit in hepatocellular carcinoma but not in other tumor types tested in a Phase 1 clinical trial on all solid tumors, consistent with the hepatic source of BMP9 (unpublished work presented at the ASCO 2014 meeting).

Q3. What about lymphatic vessels—are these involved in HHT?

Loss of *Alk1* leads to enlarged lymphatic vessels in mouse models [50], similar to the effect of *Alk1* depletion in vascular endothelial cells, which results in increased endothelial cell proliferation. Endoglin is expressed on lymphatic vessels (although at lower levels than blood vessel endothelium) so we also now need to examine whether there is a lymphatic phenotype in *Eng* mutant mice.

Q4. Do the different roles of ALK1 and endoglin in the TGF β /BMP signaling pathway explain their different phenotypes?

Overall it was surprising how similar the clinical phenotypes of HHT1 and HHT2 actually were in light of the different signaling roles of endoglin and ALK1, with endoglin being a co-receptor for BMP9/10, TGF β 1 and

TGF β 3, and ALK1 being a signaling receptor with a high affinity for BMP9 & 10.

In the field of cancer research, ALK1 is generally considered to be a pro-angiogenic molecule. Thus, targeting ALK1 would provide an anti-angiogenic therapy to reduce tumor growth. However, in HHT research, BMP9 signaling through ALK1 is considered to have an anti-angiogenic effect. The challenge therefore is how to reconcile these two opposing views. It is possible that BMP9 has a biphasic response in endothelial cells, parallel to the known biphasic effects of TGF β 1 in cancer, the different effects depending on the cancer stage (TGF β is tumor-protective at early stages but pro-tumorigenic at later stages). Also, as TGF β /BMP signaling is very context dependent, the physiological situation is really important to take into account. This is especially important when considering the outcomes of in vitro culture studies.

In terms of signaling, it is not known whether AVM are due to defects in canonical (SMAD) or non-canonical (e.g. MAPK) signaling pathways. ERK and AKT signaling are both increased in *ALK1* mutant endothelial cells and inhibition of VEGFR2 rescues the AVM phenotype of the *Alk1*-inducible knockout (*iKO*) neonatal mouse retina, although not in the dermal wound healing model. The results from these mouse models were presented in more detail by Ola and colleagues (see Abstract OR45) and Oh and colleagues (see Abstract OR18) during the symposium and the possibility of different pro-angiogenic mechanisms at work in neonatal angiogenesis models versus wound healing models was discussed. The corollary of this argument is that different rescue mechanisms may be required depending on whether the AVM form under conditions of normal developmental angiogenesis or in the context of pathological angiogenesis.

There was a general consensus that the TGF β type I receptor (ALK5) is expressed in endothelial cells, despite an earlier publication to the contrary. Also, the *Alk5* (and *Tgfb2*) endothelial specific knockout (KO) mice have a vascular phenotype. However the role of TGF β signaling in HHT is unclear. It may play a secondary role, with the primary HHT pathway being BMP9/10-endoglin-ALK1 signaling.

Q5. Why are AVM more dynamic in the *Eng*-iKO mouse than in the *Alk1*-iKO mouse?

Garrido-Martin and colleagues have directly compared the dynamics of AVM formation in a dermal wound model in the absence of endothelial endoglin or absence of endothelial ALK1 [38]. It was felt that there was maybe too little understanding of the dynamics of AVM development in the different models to comment at this stage.

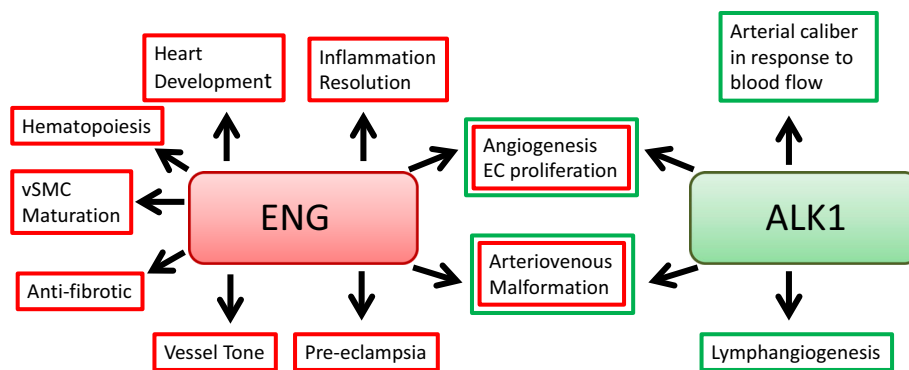


Fig. 2 Overlapping and different reported roles of ALK1 and endoglin. ALK1 (also known as ACVRL1) and endoglin (ENG) have been reported to have overlapping roles in angiogenesis, arteriovenous malformations. However, different roles have also been reported; for example, endoglin has been shown to be associated

with pre-eclampsia whilst ALK1 is associated with lymphangiogenesis. The question raised is whether these reports reflect true differences in the roles of these two genes or just incomplete analyses?

Q6. Are the different reported roles of ALK1 and endoglin (summarized in Fig. 2) due to real differences in function or incomplete analyses?

Sol-endoglin is associated with pre-eclampsia, but it is not yet known if there is a soluble form of ALK1 that could have any role in this disorder. Nor is it known whether the non-overlapping roles of endoglin and ALK1, e.g. role of endoglin in regulating fibrosis, has any relevance to HHT. Endoglin has a role in regulating eNOS activity and vascular tone, whilst a similar role has been reported for ALK1 in regulating eNOS coupling. These roles of endoglin and ALK1 in regulating vascular tone could be critical for HHT.

Workshop 3: What is the current role of medications in the treatment of HHT-related epistaxis?

Urban Geithoff and James R. Gossage

Epistaxis is the most frequent symptom of HHT and can severely affect quality of life. Although multiple drugs have been studied for HHT related epistaxis (HRE), high-quality evidence is sparse and therefore it is difficult for the clinician to make an informed choice. The goals of this workshop were to critically review the current published evidence for various therapeutic agents in HRE and to discuss their optimal use in clinical practice. Throughout this workshop the moderators posed various clinical practice questions to the participants—approximately 40–50 clinical experts in HHT. All studies cited below refer to patients with HRE unless otherwise noted.

Antifibrinolytics

Probably the best evidence exists for tranexamic acid (TA), an antifibrinolytic drug. Two randomized controlled trials (RCT) showed that TA, 1 gm thrice daily, significantly reduced nosebleeds in HRE and showed a trend toward reduced hemoglobin levels versus placebo [51, 52]. Case reports have suggested a benefit from topical TA but a recent RCT in 61 patients did not show a significant effect over placebo (see Abstract OR46). When queried by the moderators, 80–90 % of the audience agreed that TA was probably effective in HRE and some have seen improved hemoglobin. Thrombosis is frequently quoted as a potential complication of TA. However, none of the participants had ever seen a thrombotic event resulting from the use of TA in HRE. Several participants noted that TA seems to reduce the intensity and duration of HRE more than the frequency, and sometimes the result can be dramatic. Other conclusions included: typical starting doses are 650–1300 mg tid; TA should be stopped if no treatment effect is visible after several weeks; and the lowest effective dose should be sought.

There are only case series and case reports about ϵ -aminocaproic acid, another antifibrinolytic drug. It is probably similarly effective, but in vitro it is only 10 % as potent as TA. Most participants had limited experience with this agent.

Anti-VEGF therapies

Plasma vascular endothelial growth factor (VEGF) is elevated in HHT [53]. Multiple case series and case reports of at least 60 patients, with the largest including 25 patients [54], have described a reduction in HRE from intravenous

bevacizumab (BEV, an anti-VEGF antibody). The usual dose has been 5 mg/kg every 2 weeks for 6 courses, followed by additional doses every 3–12 months as needed. One uncontrolled prospective study of 6 patients suggested benefit from 0.125 mg/kg every 4 weeks [55]. A RCT of submucosal nasal injection of 100 mg BEV showed a trend toward improved HRE over placebo in 15 patients [56]. Two RCT of intranasal BEV spray in 97 patients showed no significant benefit over placebo [57] (see Abstract OR46). Overall, most participants felt confident that intravenous BEV is effective and well tolerated in HRE. Unanswered questions include: the optimal dose, duration of maintenance therapy, and long-term side effects for intravenous BEV; whether topical use of BEV at higher doses or gel vehicles might be more effective; and whether some patients have a rebound worsening of epistaxis after stopping BEV.

Thalidomide is another drug with antiangiogenic properties. A report of 7 patients [58] and several case reports suggested benefit. Typical doses have been 50–200 mg daily. One report of 12 patients showed that 8 patients discontinued thalidomide due to side effects (see Abstract P49). About 50 % of participants felt that thalidomide was effective, though also the drug of last resort due to severe side effects such as thrombotic events and peripheral neuropathy. One participant reported anecdotal benefit in about 25 patients using 50 mg daily or every other day.

Hormonal therapies

Estrogens have been extensively reported on in HRE but the evidence is mostly low quality. Potential mechanisms of benefit include induction of squamous metaplasia of nasal mucosa and prothrombotic effects. In a thorough review of mostly uncontrolled studies, Jameson concluded that high dose estradiol (0.25–1 mg daily) is probably effective but also associated with potentially serious side effects; contraceptive doses of estrogen (0.02–0.05 mg daily) are possibly effective [59]. A RCT in 10 patients with bleeding gastrointestinal angiodysplasias—6 of whom had HHT—showed decreased blood transfusion for combined estrogen and progesterone versus placebo [60]. However, a RCT of estradiol valerate 4 mg daily in 31 patients with HRE did not show a significant improvement but only a trend [61]. It was discussed that a progesterone component might be important for the efficacy and that this efficacy may be especially high for those progesterones with a higher frequency of thrombotic side effects. Several case series and one small unblinded RCT [62] have suggested that topical estriol 0.1 % ointment is effective in reducing HRE. However, this study used different ointment bases for placebo and estriol. Additionally,

a RCT in 58 patients showed that estriol 0.1 % nasal spray was less effective than placebo for some endpoints (see Abstract OR46). Participants suggested that the positive effects seen in practice and case series might have resulted from the humidifying properties of the drug incipient (e.g. peanut oil or petrolatum). The main side effects noted by participants have been mood changes and breast enlargement/tenderness.

Tamoxifen is a selective estrogen receptor modulator (SERM). A double-blind RCT in 25 patients with HRE found a significant improvement in nosebleeds and haemoglobin for tamoxifen 20 mg daily versus placebo [63]. A prospective uncontrolled study of raloxifene, another SERM, also suggested benefit [64]. However, both studies had methodologic limitations and some participants observed that the effect of tamoxifen often waned over time.

Overall, 10–30 % of participants felt that hormones are beneficial in HRE, but many participants had never used these drugs for HRE.

Beta blockers

Beta blockers like propranolol and timolol have been reported to reduce nosebleeds when given topically to 8 patients (from several small series) or to 7 children with idiopathic epistaxis [65]. Potential mechanisms of action include vasoconstriction, inhibition of VEGF, and various effects on endothelial cells. The clinical experience of participants was mixed—most had not tried beta blockers and those who had were mostly unimpressed with results. One participant was optimistic and thought that gels might be more effective than drops or sprays (see Abstract OR9).

Other therapies

N-acetylcysteine 600 mg thrice daily reduced nosebleeds in an observational pilot study of 43 patients [66]. The effects were especially seen in male HHT1 patients. Potential mechanisms include oxide scavenging and nasal humidification through the side effect of rhinorrhea. As side effects of this over-the-counter drug are negligible, the majority of participants agreed that it is worth trying, though the true benefit remains unknown.

The importance of nasal mucosal humidification has been stated in numerous publications on HHT [16]. A recent observational study of sesame oil supported this experience [67]. We discussed whether topical treatments with different consistencies (e.g. saline, gels, and ointments) might have different efficacies, but there are no data to answer this question.

Conclusions

The participants agreed that preventive nasal humidification is the most important first step in treating HRE. Addition of various drugs to saline has thus far proven no more effective than saline alone. However, the efficacy of drugs added to gels or ointments has not been adequately studied. Systemic medications with few side effects like TA or *N*-acetylcysteine were regarded the next appropriate step by the participants. Alternatively, or as the next step after, the participants recommended surgery with a low risk profile, mainly endonasal coagulation (e.g. laser). Other systemic drugs like thalidomide and bevacizumab, or more invasive surgeries including septodermoplasty and nasal closure, seem more appropriate for refractory epistaxis. There are no data on combination therapy.

Workshop 4: What is the optimal management of diffuse PAVM and PAVM with reperfusion or refractory hemoptysis?

Pascal Lacombe and Scott O. Trerotola

Management of diffuse PAVM

The session began with a discussion of definitions. Diffuse pulmonary arteriovenous malformations (DPAVM) are characterized by many small arteriovenous connections, lack of normal distal pulmonary branches, and no sac [68, 69]. There is overlap between complex PAVM and DPAVM in terms of the number of feeding vessels but complex ones have a sac and diffuse ones do not. A DPAVM is like a peripheral systemic AVM with a true nidus; yet we would never treat a systemic AVM primarily with coils. So why do we do so in DPAVM? Because we cannot use glue or liquids for risk of paradoxical embolization. The extent of DPAVM is best evaluated by computed tomography (CT) in adults, or CT and pulmonary arteriography children, but only if symptomatic. Why treat a child with DPAVM? Most participants seemed not in favor of treating an asymptomatic child unless they had severe desaturation. When treating a patient with DPAVM, any simple or complex PAVM is first embolized. For the DPAVM itself, a distal to proximal embolization permits a peripheral flow redistribution towards less involved areas [69]. Results of DPAVM embolization are quite satisfactory, with an improvement in the quality of life and diminution in systemic complications [68]. But, published series have had significant morbidity and mortality even after embolization [68, 69]. Then, a discussion of *how to treat* centered on surgery versus embolization. *With embolization we create a disease we cannot control.*

While DPAVM causes bronchial and systemic supply to hypertrophy without treatment, treatment may make it worse by not treating deep enough in the nidus. This may lead to hemoptysis precipitated by cough, which can occasionally be fatal even in the absence of prodromal symptoms (see Abstract P57).

Patients with bilateral DPAVM typically have no choice but embolization or transplantation, but those with unilateral DPAVM may be surgical (lobectomy or pneumonectomy) candidates. Why consider surgery? Concerns were raised from participants about new PAVM growing after surgery; in fact this does not happen, and any small simple PAVM can still be treated with embolization, which remains the mainstay and standard-of-care for these and complex PAVM. Surgery eliminates desaturation *and* risk of hemoptysis. We can cure simple PAVM with embolization, but we only can improve DPAVM with embolization because we know now that there is an unpredictable risk of delayed hemoptysis. Usually, only a surgeon can cure DPAVM. Thus, surgery could be considered in the treatment options for non-bilateral DPAVM. However, one must not ignore risks of hemorrhage during surgery especially due to transpleural systemic-to-pulmonary collaterals. The possibility of preoperative systemic arterial embolization was discussed, as well as technical aspects; all participants agreed that very large particles (≥ 900 micron) should be used, The role of surgery as initial treatment of non-bilateral DPAVM remains unclear and will require future analysis of risk factors that may contribute to hemoptysis and long-time follow-up of patients treated with surgery.

PAVM with persistence

Persistence is defined as contrast enhancement within an embolized PAVM on CT, even when sac retraction seems complete. This occurs in 5–30 % of treated PAVM [70–72]. There are four implicated mechanisms:

- Persistent or recurrent right-to-left shunt (RTLS) by recanalization through previously deposited devices.
- Development of pulmonary artery-to-PAVM collaterals in the form of an angiographic fine or large mesh network.
- Development of systemic artery-to-PAVM collaterals from bronchial or transpleural systemic arteries (phrenic, internal mammary, intercostal) leading to a left-to-left shunt (LTLS) [73].
- Previously unidentified small feeders missed at the time of the initial embolization.

There is a constant interaction of these types of persistence: preponderant RTLS leading to systemic complications (e.g. cerebral abscess or stroke) via paradoxical emboli; balanced RTLS versus LTLS (i.e. systemic artery to

pulmonary vein) shunt with false negative pulmonary angiography (as seen in a Rasmussen aneurysm), and preponderant LTLS with risks of hemoptysis and left cardiac failure but not paradoxical emboli. There was discussion of the indications for re-embolization in case of persistence as well as the difficulty and occasional worse results in doing so. The consensus was that sac growth or recurrent symptoms would warrant treatment. The optimal approach to patients with inadequate sac retraction (i.e. <70 %) after embolization is unclear, though some favor repeat embolization.

Treated PAVM and hemoptysis

While hemoptysis is most common after DPAVM embolization, even some complex PAVM may result in hemoptysis after treatment. Surgery should be considered any time embolization results in significant hemoptysis (see Abstract P46). The vascular steal phenomenon around the PAVM is a possible cause of systemic collaterals *before* embolization. This phenomenon can be replaced by ischemic consequences of embolization, leading to systemic collaterals of the embolized area *after* embolization. Again, embolization may create another disease which is difficult to control. Hemoptysis is an uncommon symptom of an untreated PAVM, caused by tracheobronchial telangiectases (well-tolerated small volume hemoptysis), or by life-threatening rupture which can occur at any age, even early in life [69]. The mechanisms of hemoptysis in the post embolization setting might include rupture of an embolized PAVM, rupture of pulmonary-to-pulmonary mesh network or more commonly from systemic circulation (bronchial or transpleural systemic arteries) flowing towards the PAVM. Therapeutic options for hemoptysis can be explored with AngioMR 4D sequences, CT angiography, or pulmonary and/or systemic arteriography [69, 73]. AngioMR 4D permits differentiation of a RTLS (with enhancement of the PAVM in the pulmonary phase) from a LTLS (with enhancement of the PAVM in the aortic phase). Hemoptysis with a RTLS is managed with the usual techniques of pulmonary embolotherapy. However, in the setting of a LTLS, there is a risk of systemic embolization via systemic connections with the PAVM and hence pulmonary vein; thus large (≥ 900 micron) particles of polyvinyl acetate are commonly used. The late onset of fatal hemoptysis without prodromal symptoms after complex PAVM embolization raises the issue of a preventive systemic embolization. Surgery should be considered in cases of failure of systemic embolization (see above).

Acknowledgments We would like to acknowledge the financial support of Cure HHT and the scientific contributions of the attendees that made this meeting possible.

Funding This conference was supported by Cure HHT, HHT Ireland, Covidien, Medtronic, ARUP Laboratories, Genetic Diagnostic Laboratory, Boston Scientific, Actelion, Ambray Genetics, Gilead, B. Braun GeGaT, and St. Jude Medical.

Compliance with ethical standards

Conflict of interest J. Gossage is a part time paid Medical Director of Cure HHT; C. Hughes was reimbursed for meeting expenses by Cure HHT; the other authors report no conflicts.

References

- Shovlin CL, Hughes JM, Tuddenham EG, Temperley I, Perembelony YF, Scott J, Seidman CE, Seidman JG (1994) A gene for hereditary haemorrhagic telangiectasia maps to chromosome 9q3. *Nat Genet* 6:205–209
- Johnson DW, Berg JN, Baldwin MA, Gallione CJ, Marondel I, Yoon SJ, Stenzel TT, Speer M et al (1996) Mutations in the activin receptor-like kinase 1 gene in hereditary haemorrhagic telangiectasia type 2. *Nat Genet* 13:189–195
- Gallione CJ, Repetto GM, Legius E, Rustgi AK, Schelley SL, Tejpar S, Mitchell G, Drouin E et al (2004) A combined syndrome of juvenile polyposis and hereditary haemorrhagic telangiectasia associated with mutations in MADH4 (SMAD4). *Lancet* 363:852–859
- McDonald J, Damjanovich K, Millson A, Wooderchak W, Chibuk JM, Stevenson DA, Gedge F, Bayrak-Toydemir P (2011) Molecular diagnosis in hereditary hemorrhagic telangiectasia: findings in a series tested simultaneously by sequencing and deletion/duplication analysis. *Clin Genet* 79:335–344
- McDonald J, Wooderchak-Donahue W, VanSant Webb C, Whitehead K, Stevenson DA, Bayrak-Toydemir P (2015) Hereditary hemorrhagic telangiectasia: genetics and molecular diagnostics in a new era. *Front Genet* 6(1):1–8. doi:10.3389/fgene.2015.00001
- Bushby K, Finkel R, Wong B, Barohn R, Campbell C, Comi GP, Connolly AM, Day JW et al (2014) Ataluren treatment of patients with nonsense mutation dystrophinopathy. *Muscle Nerve* 50(4):477–487
- Kerem E, Konstan MW, De Boeck K, Accurso FJ, Sermet-Gaudelus I, Wilschanski M, Elborn JS et al (2014) Ataluren for the treatment of nonsense-mutation cystic fibrosis: a randomised, double-blind, placebo-controlled phase 3 trial. *Lancet Respir Med* 2(7):539–547
- Wooderchak-Donahue W, McDonald J, O'Fallon B, Upton PD, Li W, Roman BL, Young S, Plant P et al (2013) BMP9 mutations cause a vascular anomaly syndrome with phenotypic overlap with hereditary hemorrhagic telangiectasia. *Am J Hum Genet* 93:1–8
- Rigelsky CM, Jennings C, Lehtonen R, Minai OA, Eng C, Aldred MA (2008) BMP2 mutation in a patient with pulmonary arterial hypertension and suspected hereditary hemorrhagic telangiectasia. *Am J Med Genet A* 146A(19):2551–2556
- Larrivée B, Prahst C, Gordon E, del Toro R, Mathivet T, Duarte A, Simons M, Eichmann A (2012) ALK1 signaling inhibits angiogenesis by cooperating with the Notch pathway. *Dev Cell* 22(3):489–500
- Cartin-Ceba R, Swanson KL, Krowka MJ (2013) Pulmonary arteriovenous malformations. *Chest* 144:1033–1044
- Kjeldsen AD, Oxhøj H, Andersen PE, Green A, Vase P (2000) Prevalence of pulmonary arteriovenous malformations (PAVM) and occurrence of neurological symptoms in patients with hereditary haemorrhagic telangiectasia (HHT). *J Intern Med* 248:255–262

13. Moussouttas M, Fayad P, Rosenblatt M, Hashimoto M, Pollak J, Henderson K, Ma TY, White RI (2000) Pulmonary arteriovenous malformations: cerebral ischemia and neurologic manifestations. *Neurology* 55:959–964
14. Shovlin CL, Jackson JE, Bamford KB, Jenkins IH, Benjamin AR, Ramadan H, Kulinskaya E (2008) Primary determinants of ischaemic stroke/brain abscess risks are independent of severity of pulmonary arteriovenous malformations in hereditary haemorrhagic telangiectasia. *Thorax* 63:259–266
15. Velthuis S, Buscarini E, van Gent MW, Gazzaniga P, Manfredi G, Danesino C, Schonewille WJ, Westermann CJ et al (2013) Grade of pulmonary right-to-left shunt on contrast echocardiography and cerebral complications: a striking association. *Chest* 144:542–548
16. Faughnan ME, Palda VA, Garcia-Tsao G, Geisthoff UW, McDonald J, Proctor DD, Spears J, Brown DH et al (2011) International guidelines for the diagnosis and management of hereditary haemorrhagic telangiectasia. *J Med Genet* 48:73–87
17. Velthuis S, Buscarini E, Gossage JR, Snijder RJ, Mager JJ, Post MC (2015) Clinical implications of pulmonary shunting on saline contrast echocardiography. *J Am Soc Echocardiogr* 28:255–263
18. Elliott JE, Nigam SM, Laurie SS, Beasley KM, Goodman RD, Hawn JA, Gladstone IM, Chesnutt MS, Lovering AT (2013) Prevalence of left heart contrast in healthy, young, asymptomatic humans at rest breathing room air. *Respir Physiol Neurobiol* 188:71–78
19. Lovering AT, Stickland MK, Amann M, Murphy JC, O'Brien MJ, Hokanson JS, Eldridge MW (2008) Hyperoxia prevents exercise-induced intrapulmonary arteriovenous shunt in healthy humans. *J Physiol* 586(18):4559–4565
20. Li W, Niu B, Henderson K, Northrup V, Pollak JS, Trow T, Fahey J, White RI Jr (2011) Reproducibility of oxygen saturation monitoring during six-minute walk test and exercise stress test in patients with pulmonary arteriovenous malformations associated with hereditary hemorrhagic telangiectasia. *Pediatr Cardiol* 32:590–594
21. Faughnan ME, Thabet A, Mei-Zahav M, Colombo M, Macluskay I, Hyland RH, Pugash RA, Chait P, Henderson KJ, White RI (2004) Pulmonary arteriovenous malformations in children: outcomes of transcatheter embolotherapy. *J Pediatr* 145:826–831
22. Galiè N, Hoepfer MM, Humbert M, Torbicki A, Vachiery JL, Barbera JA, Beghetti M, Corris P et al (2009) Guidelines for the diagnosis and treatment of pulmonary hypertension: the Task Force for the Diagnosis and Treatment of Pulmonary Hypertension of the European Society of Cardiology (ESC) and the European Respiratory Society (ERS), endorsed by the International Society of Heart and Lung Transplantation (ISHLT). *Eur Heart J* 30:2493–2537
23. Arthur HM, Ure J, Smith AJ, Renforth G, Wilson DI, Torsney E, Charlton R, Parums DV et al (2000) Endoglin, an ancillary TGFbeta receptor, is required for extraembryonic angiogenesis and plays a key role in heart development. *Dev Biol* 217:42–53
24. Bourdeau A, Dumont DJ, Letarte M (1999) A murine model of hereditary hemorrhagic telangiectasia. *J Clin Invest* 104:1343–1351
25. Mahmoud M, Allinson KR, Zhai Z, Oakenfull R, Ghandi P, Adams RH, Fruttiger M, Arthur HM (2010) Pathogenesis of arteriovenous malformations in the absence of endoglin. *Circ Res* 106:1425–1433
26. Oh SP, Seki T, Goss KA, Imamura T, Yi Y, Donahoe PK, Li L, Miyazono K et al (2000) Activin receptor-like kinase 1 modulates transforming growth factor- β 1 signaling in the regulation of angiogenesis. *Proc Natl Acad Sci USA* 97:2626–2631
27. Park SO, Lee YJ, Seki T, Hong KH, Fliess N, Jiang Z, Park A, Wu X et al (2008) ALK5- and TGFBR2-independent role of ALK1 in the pathogenesis of hereditary hemorrhagic telangiectasia type 2. *Blood* 111:633–642
28. Park SO, Wankhede M, Lee YJ, Choi EJ, Fliess N, Choe SW, Oh SH, Walter G et al (2009) Real-time imaging of de novo arteriovenous malformation in a mouse model of hereditary hemorrhagic telangiectasia. *J Clin Invest* 119:3487–3496
29. Roman BL, Pham VN, Lawson ND, Kulik M, Childs S, Lekven AC, Garrity DM, Moon RT et al (2002) Disruption of *acvr11* increases endothelial cell number in zebrafish cranial vessels. *Development* 129:3009–3019
30. Srinivasan S, Hanes MA, Dickens T, Porteous ME, Oh SP, Hale LP, Marchuk DA (2003) A mouse model for hereditary hemorrhagic telangiectasia (HHT) type 2. *Hum Mol Genet* 12:473–482
31. Urness LD, Sorensen LK, Li DY (2000) Arteriovenous malformations in mice lacking activin receptor-like kinase-1. *Nat Genet* 26:328–331
32. Bourdeau A, Cymerman U, Paquet ME, Meschino W, McKinnon WC, Guttmacher AE, Becker L, Letarte M (2000) Endoglin expression is reduced in normal vessels but still detectable in arteriovenous malformations of patients with hereditary hemorrhagic telangiectasia type 1. *Am J Pathol* 156:911–923
33. Hawinkels LJ, Kuiper P, Wiercinska E, Verspaget HW, Liu Z, Pardali E, Sier CF, ten Dijke P (2010) Matrix metalloproteinase-14 (MT1-MMP)-mediated endoglin shedding inhibits tumor angiogenesis. *Cancer Res* 70:4141–4150
34. Valbuena-Diez AC, Blanco FJ, Oujo B, Langa C, Gonzalez-Nunez M, Llano E, Pendas AM, Diaz M et al (2012) Oxysterol-induced soluble endoglin release and its involvement in hypertension. *Circulation* 126:2612–2624
35. Mallet C, Lamribet K, Giraud S, Dupuis-Girod S, Feige JJ, Bailly S, Tillet E (2014) Functional analysis of endoglin mutations from hereditary hemorrhagic telangiectasia type 1 patients reveals different mechanisms for endoglin loss of function. *Hum Mol Genet* 24(4):1142–1154
36. Corti P, Young S, Chen CY, Patrick MJ, Rochon ER, Pekkan K, Roman BL (2011) Interaction between *alk1* and blood flow in the development of arteriovenous malformations. *Development* 138:1573–1582
37. Choi EJ, Walker EJ, Shen F, Oh SP, Arthur HM, Young WL, Su H (2012) Minimal homozygous endothelial deletion of *Eng* with VEGF stimulation is sufficient to cause cerebrovascular dysplasia in the adult mouse. *Cerebrovasc Dis* 33:540–547
38. Garrido-Martin EM, Nguyen HL, Cunningham TA, Choe SW, Jiang Z, Arthur HM, Lee YJ, Oh SP (2014) Common and distinctive pathogenetic features of arteriovenous malformations in hereditary hemorrhagic telangiectasia 1 and hereditary hemorrhagic telangiectasia 2 animal models—brief report. *Arterioscler Thromb Vasc Biol* 34:2232–2236
39. Han C, Choe SW, Kim YH, Acharya AP, Keselowsky BG, Sorg BS, Lee YJ, Oh SP (2014) VEGF neutralization can prevent and normalize arteriovenous malformations in an animal model for hereditary hemorrhagic telangiectasia 2. *Angiogenesis* 17:823–830
40. Hao Q, Zhu Y, Su H, Shen F, Yang GY, Kim H, Young WL (2010) VEGF induces more severe cerebrovascular dysplasia in endoglin than in *alk1* mice. *Transl Stroke Res* 1:197–201
41. Walker EJ, Su H, Shen F, Choi EJ, Oh SP, Chen G, Lawton MT, Kim H et al (2011) Arteriovenous malformation in the adult mouse brain resembling the human disease. *Ann Neurol* 69:954–962
42. Bayrak-Toydemir P, McDonald J, Markewitz B, Lewin S, Miller F, Chou LS, Gedge F, Tang W et al (2006) Genotype–phenotype correlation in hereditary hemorrhagic telangiectasia: mutations and manifestations. *Am J Med Genet A* 140(5):463–470

43. Berg J, Porteous M, Reinhardt D, Gallione C, Holloway S, Umasunthar T, Lux A, McKinnon W et al (2003) Hereditary haemorrhagic telangiectasia: a questionnaire based study to delineate the different phenotypes caused by endoglin and ALK1 mutations. *J Med Genet* 40(8):585–590
44. Kjeldsen AD, Møller TR, Brusgaard K, Vase P, Andersen PE (2005) Clinical symptoms according to genotype amongst patients with hereditary haemorrhagic telangiectasia. *J Intern Med* 258(4):349–355
45. Letteboer TG, Mager HJ, Snijder RJ, Lindhout D, Ploos van Amstel HK, Zanen P, Westermann KJ (2008) Genotype–phenotype relationship for localization and age distribution of telangiectases in hereditary hemorrhagic telangiectasia. *Am J Med Genet A* 146A(21):2733–2739
46. Letteboer TG, Mager JJ, Snijder RJ, Koeleman BP, Lindhout D, Ploos van Amstel JK, Westermann CJ (2006) Genotype–phenotype relationship in hereditary haemorrhagic telangiectasia. *J Med Genet* 43(4):371–377
47. Shovlin CL (2010) Hereditary haemorrhagic telangiectasia: pathophysiology, diagnosis and treatment. *Blood Rev* 24(6):203–219
48. Wever-Pinzon O, Selzman CH, Drakos SG, Saidi A, Stoddard GJ, Gilbert EM, Labedi M, Reid BB et al (2013) Pulsatility and the risk of nonsurgical bleeding in patients supported with the continuous-flow left ventricular assist device HeartMate II. *Circ Heart Fail* 6(3):517–526
49. Tual-Chalot S, Mahmoud M, Allinson KR, Redgrave RE, Zhai Z, Oh SP, Fruttiger M, Arthur HM (2014) Endothelial depletion of *Acvr11* in mice leads to arteriovenous malformations associated with reduced endoglin expression. *PLoS ONE* 9(6):e98646
50. Yoshimatsu Y, Lee YG, Akatsu Y, Taguchi L, Suzuki HI, Cunha SI, Maruyama K, Suzuki Y (2013) Bone morphogenetic protein-9 inhibits lymphatic vessel formation via activin receptor-like kinase 1 during development and cancer progression. *Proc Natl Acad Sci USA* 110(47):18940–18945
51. Gaillard S, Dupuis-Girod S, Boutitie F, Riviere S, Moriniere S, Hatron PY, Manfredi G, Kaminsky P et al (2014) Tranexamic acid for epistaxis in hereditary hemorrhagic telangiectasia patients: a European cross-over controlled trial in a rare disease. *J Thromb Haemost* 12:1494–1502
52. Geisthoff UW, Seyfert UT, Kubler M, Bieg B, Plinkert PK, Konig J (2014) Treatment of epistaxis in hereditary hemorrhagic telangiectasia with tranexamic acid—a double-blind placebo-controlled cross-over phase IIIB study. *Thromb Res* 134:565–571
53. Cirulli A, Liso A, D’Ovidio F, Mestice A, Pasculli G, Gallitelli M, Rizzi R, Specchia G, Sabba C (2003) Vascular endothelial growth factor serum levels are elevated in patients with hereditary hemorrhagic telangiectasia. *Acta Haematol* 110:29–32
54. Dupuis-Girod S, Ginon I, Saurin JC, Marion D, Guillot E, Decullier E, Roux A, Carette MF et al (2012) Bevacizumab in patients with hereditary hemorrhagic telangiectasia and severe hepatic vascular malformations and high cardiac output. *JAMA* 307:948–955
55. Thompson AB, Ross DA, Berard P, Figueroa-Bodine J, Livada N, Richer SL (2014) Very low dose bevacizumab for the treatment of epistaxis in patients with hereditary hemorrhagic telangiectasia. *Allergy Rhinol* 5:e91–e95. doi:10.2500/ar.2014.5.0091
56. Riss D, Burian M, Wolf A, Kranebitter V, Kaider A, Arnoldner C (2015) Intranasal submucosal bevacizumab for epistaxis in hereditary hemorrhagic telangiectasia: a double-blind, randomized, placebo-controlled trial. *Head Neck* 37(6):783–787
57. Dupuis-Girod S, Ambrun A, Decullier E, Samson G, Roux A, Fargeton AE, Rioufol C, Schwiertz V et al (2014) ELLIPSE Study: a Phase I study evaluating the tolerance of bevacizumab nasal spray in the treatment of epistaxis in hereditary hemorrhagic telangiectasia. *MAbs* 6:794–799
58. Lebrin F, Srun S, Raymond K, Martin S, van den Brink S, Freitas C, Breant C, Mathivet T et al (2010) Thalidomide stimulates vessel maturation and reduces epistaxis in individuals with hereditary hemorrhagic telangiectasia. *Nat Med* 16:420–428
59. Jameson JJ, Cave DR (2004) Hormonal and antihormonal therapy for epistaxis in hereditary hemorrhagic telangiectasia. *Laryngoscope* 114:705–709
60. Van Cutsem E, Rutgeerts P, Vantrappen G (1990) Treatment of bleeding gastrointestinal vascular malformations with oestrogen-progesterone. *Lancet* 335:953–955
61. Vase P (1981) Estrogen treatment of hereditary hemorrhagic telangiectasia. A double-blind controlled clinical trial. *Acta Med Scand* 209:393–396
62. Bergler W, Sadick H, Gotte K, Riedel F, Hormann K (2002) Topical estrogens combined with argon plasma coagulation in the management of epistaxis in hereditary hemorrhagic telangiectasia. *Ann Otol Rhinol Laryngol* 111:222–228
63. Yaniv E, Preis M, Hadar T, Shvero J, Haddad M (2009) Anti-estrogen therapy for hereditary hemorrhagic telangiectasia: a double-blind placebo-controlled clinical trial. *Laryngoscope* 119:284–288
64. Albinana V, Bernabeu-Herrero ME, Zarrabeitia R, Bernabeu C, Botella LM (2010) Estrogen therapy for hereditary haemorrhagic telangiectasia (HHT): effects of raloxifene, on endoglin and ALK1 expression in endothelial cells. *Thromb Haemost* 103:525–534
65. Bjelakovic B, Bojanovic M, Lukic S, Saranac L, Vukomanovic V, Prijic S, Zivkovic N, Randjelovic D (2013) The therapeutic efficacy of propranolol in children with recurrent primary epistaxis. *Drug Des Devel Ther* 7:127–129
66. de Gussem EM, Snijder RJ, Disch FJ, Zanen P, Westermann CJ, Mager JJ (2009) The effect of *N*-acetylcysteine on epistaxis and quality of life in patients with HHT: a pilot study. *Rhinology* 47:85–88
67. Reh DD, Hur K, Merlo CA (2013) Efficacy of a topical sesame/rose geranium oil compound in patients with hereditary hemorrhagic telangiectasia associated epistaxis. *Laryngoscope* 123:820–822
68. Faughnan ME, Lui YW, Wirth JA, Pugash RA, Redelmeier DA, Hyland RH, White RI (2000) Diffuse pulmonary arteriovenous malformations: characteristics and prognosis. *Chest* 117:31–38
69. Lacombe P, Lacout A, Marcy PY, Binsse S, Sellier J, Bensalah M, Chinnet T, Bourgault-Villada I et al (2013) Diagnosis and treatment of pulmonary arteriovenous malformations in hereditary hemorrhagic telangiectasia: an overview. *Diagn Interv Imaging* 94:835–848
70. Lacombe P, Lagrange C, El Hajjam M, Chinnet T, Pelage JP (2005) Reperfusion of complex pulmonary arteriovenous malformations after embolization: report of three cases. *Cardiovasc Intervent Radiol* 28:30–35
71. Milic A, Chan RP, Cohen JH, Faughnan ME (2005) Reperfusion of pulmonary arteriovenous malformations after embolotherapy. *J Vasc Interv Radiol* 16:1675–1683
72. Pollak JS, Saluja S, Thabet A, Henderson KJ, Denbow N, White RI (2006) Clinical and anatomic outcomes after embolotherapy of pulmonary arteriovenous malformations. *J Vasc Interv Radiol* 17:35–45
73. Brilllet PY, Dumont P, Bouaziz N, Duhamel A, Laurent F, Remy J, Remy-Jardin M (2007) Pulmonary arteriovenous malformation treated with embolotherapy: systemic collateral supply at multi-detector CT angiography after 2–20-year follow-up. *Radiology* 242:267–276